



1. Orthopedic Surgery; Specialist Orthopedic Surgery, Orthopedic Unit, Dr. Sulaiman Al-Habib hospital, Riyadh, KSA.
2. Orthopedic Surgery; Assistant Professor, Orthopedic surgery Dr. Ruth K.M. Pauf Civil Hospital, Karachi.
3. Orthopedic Surgery; Specialist Orthopedic Surgery, Orthopedic Unit Dr. Sulaiman Al-Habib hospital, Riyadh, KSA.
4. Orthopedic Surgery; Senior Registrar, Orthopedic department Liaquat University of Medical & Health Sciences, Jamshoro.
5. Orthopedics Surgeon; Jinnah Post Graduate Medical Center, Karachi.
6. Assistant Professor, Department of Pathology, Isra University, Hyderabad

\*=corresponding author  
[drazfarkhaznda.ksa@gmail.com](mailto:drazfarkhaznda.ksa@gmail.com)

## Radiological outcome of non-displaced femoral neck fractures in younger patients using cannulated screws fixation technique.

Syed Alam Zeb<sup>1</sup>, Muhammad Tahir Lakho<sup>2</sup>, Muhammad Azfar Khanzada<sup>3,\*</sup>, Zulfikar Ali Memon<sup>4</sup>, Bashir Ahmed<sup>5</sup>, Safiya Javed<sup>6</sup>.

### Abstract:

**Introduction:** Femoral neck fractures are known as challenging and complicated trauma in orthopedic surgeries. Multiple cannulated screws techniques have been commonly used methods for the management of these fractures.

**Objective:** To evaluate the radiological outcome of the non-displaced type of femoral neck fractures among younger patients by applying cannulated screws fixation technique.

**Methodology:** This prospective study was conducted from October 2018 to March 2020 at Orthopedic Surgery Department, Liaquat University Hospital, Hyderabad /Jamshoro. Non-random consecutive sampling technique was applied for participant selection. All the patients belong to either gender between age 25 and 45 years presented in the orthopedic surgery outpatient unit or emergency with non-displaced fracture type I & II of neck of femur classified on Garden variety classification were included in the study. All the patients underwent surgery using cannulated screws fixation technique. The radiological outcome was evaluated based on non-union and avascular necrosis using post-operative radiographs and MRI of the hip joint. The collected data was analyzed using SPSS ver. 23.

**Results:** Among 258 patients, 97(61.39) were males and 59(37.34) were females. The mean age of patients was  $34.79 \pm 8.22$  years while the mean span of fracture was  $3.54 \pm 1.47$  days. Non-union was observed in 12.94% of patients and avascular necrosis was observed in 6.47% of cases. Significant association of non-union was observed with age and duration of fracture.

**Conclusion:** Neck of femur fracture fixation through cannulated hip screws remains an effective option with limited or minimal postoperative complications among younger patients.

**Keywords:** Cannulated hip screws, Radiological, non-displaced fractures.

**Introduction:**

Femoral neck fracture (FNF) is complicated and challenging to manage. Nearly half of the hip fractures are comprised fracture of femoral neck region<sup>1</sup>. Among the young people aged about 25 to 45 years, these fracture results from the high energy trauma. While in older age group patients; minimal to moderate energy trauma may result in the FNF<sup>2,3</sup>. Depending upon the age group and pattern of fracture as well as complexity, number of treatment techniques are available for the management of femoral neck fractures. For the treatment of non-displaced fractures of femoral neck, multiple cannulated screws technique has been commonly used method for the management of FNF<sup>4,5</sup>. Despite management of these fracture after apposite treatment, some patients likely to develop different complications like nonunion and/or avascular necrosis (AVN) of the femoral head due to repressed arterial nutrition to the head<sup>6</sup>. Several responsible factors are reported that are related to the high frequency of complications in FNF<sup>7</sup>. These factors include; pattern of the fracture, reduction accuracy, placement sites of metal implants and time interval between injury/trauma and surgery. Incidences of such complications may be reduced if these fractures are properly stabilized internally by the cannulated screws<sup>5,8,9</sup>.

Although, replacement of hip joint is presented to be the effective solution for elderly patients with FNF not only to facilitate the early rehabilitation but also for reducing the risk of surgical reversal. So, the techniques that preserve the original joints are preferred for relatively younger patients with FNF<sup>10</sup>.

**Objective:**

The study was designed to evaluate the radiological outcome of the non-displaced type of femoral neck fractures among younger patients who underwent the surgery applying Cannulated screws fixation technique.

**Methodology:**

This prospective study was conducted at Orthopedic Surgery Department of Liaquat University Hospital, Hyderabad /Jamshoro from October 2017 to October 2020. Non-random consecutive sampling technique was applied for participant selection. All the patients belong to either gender between age 25 and 45 years, presented in the orthopedic surgery out-patient unit or emergency, with non-displaced fracture type I & II

of neck of femur classified on Garden's classification were included in the study. Patient below and above the selected age group, with displaced fractures were excluded from the study.

After getting informed consent from patients or their attendant demographic variables recorded. All the patients with type I and type II fractures were then underwent to the surgery by using cannulated screws fixation technique. All these surgeries were performed under the supervision of senior orthopedic consultant with experience of at least 5 years in this specific specialty. Participating patients were then followed post-operatively, the first follow-up was planned on 2<sup>nd</sup> week then 6<sup>th</sup> week and lastly after 3 months postoperatively.

**Radiographic Evaluation:**

On each follow-up, radio-graphical outcome was evaluated based on non-union using simple radiographs. The outcome of the participants was classified as "optimal outcome or complications". Optimal outcome is labelled if the angle between medial trabecular stream in femoral head and trabecular-shaft angle (medial cortex of femoral shaft) was measured from hip antero-posterior radiograph. Patients with no gap in the fracture line on x-ray observed by senior orthopedic surgeons were labelled as bone union. While complications were defined as >5 mm shortening of the femoral neck non-union/early collapse (failed to show the obliteration of the fracture gap), avascular necrosis (AVN) of the head/neck femur bone during follow-up of 3 months<sup>10</sup>. All findings were noted on predesigned proforma.

**Statistical Analysis:**

The collected information was entered and analyzed in SPSS version 23. Mean  $\pm$  Standard deviation was used to present the quantitative data while the qualitative data was presented as frequencies and percentages. Stratification was done to avoid the confounders and effect modifiers. Chi square test and/ or Fisher's exact test (whichever needed) was applied for statistical analysis. P-value was considered at significance level of < 0.05.

**Results:**

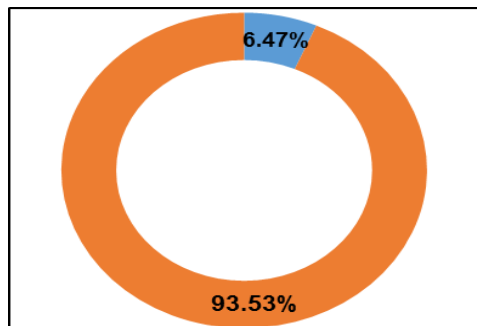
Total 201 patients between age 25 and 47 years were registered and consented to participate in the study. Out of these, majority of patients were male. The mean age of patients was 34.79 $\pm$ 8.22 years while the

mean span of fracture 3.54±1.47 days. Most of the patients were with type-II garden classification while non-union was observed in 31(12.4%). Majority (85.57%) patients had an optimal outcome. (Table I)

**Table I: General characteristics of patients (n=201).**

	n (%)
<b>Gender</b>	
Male	123(61.20)
Female	78(38.80)
<b>Age group (years)</b>	
≤ 35	86(42.78)
> 35	115(57.22)
<b>Garden classification</b>	
Type-I	90 (44.77)
Type-II	111(55.23)
<b>Non-Union</b>	
Yes	26(12.94)
No	175(87.06)
<b>Duration of Fracture</b>	
≤24 hours	93(46.26)
>24 hours	108(53.74)
<b>Hospital Stay</b>	
≤7 days	103(51.25)
>7 days	98(48.75)
<b>Outcome Status</b>	
Optimal	172(85.57)
Complications	29(14.43)

**Figure 1: : Distribution of patients with and without avascular necrosis**



Avascular necrosis in 6.47% patients

The findings of bony nonunion and its association with different study variables is shown in table 2. There was a statistically significant relation (p <0.05) between non-union of bones with age group and duration of fracture. (Table II)

**Table II: Relation between non-union and different study variables (n=201)**

	n (%)		p-value
	Yes= 26 (12.94%)	No= 175 (87.06%)	
<b>Gender</b>			
Male	18 (69.23)	105 (60.00)	0.367
Female	8(30.77)	70(40.00)	
<b>Age Group</b>			
≤35 years	5(19.23)	81(46.28)	0.009 €
>35 years	21 (80.77)	94 (53.72)	
<b>Duration of fracture</b>			
≤24 hours	22(84.62)	71(40.57)	0.000 €
>24 hours	4(15.38)	104(59.43)	
<b>Garden Classification</b>			
Type-I	12(46.16)	78(44.57)	0.879
Type-II	14(53.84)	97(55.43)	
<b>Hospital stay</b>			
≤7 days	15(57.70)	88(50.28)	0.480
>7 days	11(42.30)	87(49.72)	

€= Statistically significant (chi square test)

**Table III: Relationship of avascular necrosis with different study variables (n=201)**

	n (%)		P-Value
	Yes (n=13)	No (n=188)	
<b>Gender</b>			
Male	7(53.85)	116(61.70)	0.574
Female	6(46.15)	72(38.30)	
<b>Age Group</b>			
≤35 years	6(46.15)	80(42.55)	0.799
>35 years	7(53.85)	108(57.45)	
<b>Duration of fracture</b>			
≤24 hours	7(53.85)	86(45.75)	0.931
>24 hours	6(46.15)	102(54.25)	
<b>Hospital stay</b>			
≤7 days	8(61.54)	95(50.53)	0.442
>7 days	5(38.46)	93(49.47)	
<b>Garden Classification</b>			
Type-I	7 (84.62)	83(42.02)	0.496
Type-II	6(15.38)	105(57.98)	

The relation between avascular necrosis with other study variable are presented in table III. There was a no statistically significant relation between avascular necrosis and gender, age, duration of fracture, hospital stay as well as type of fracture. (Table III)

#### **Discussion:**

Protecting and safeguarding the blood supply to the head of femur for providing accurate anatomical reduction and absolute stability is the standard as well as preferred management choice in femur neck fracture for younger patients.<sup>11,12</sup> Irrespective to the method of treatment, FNF had a significant influence on the quality of life of patients along with a large economic burden to society. Despite the fact that number of complications are associated with internal fixation technique among the older age patients, still this technique is preferred for FNF (Garden I and II) among young age patients.<sup>10,13,14</sup> Our findings also support this, as majority (85.57%) patients didn't experience any complication. In the present study the mean age of participant was 34.79±8.22 years. With majority (61.20%) were male patients. These findings are consistent with that of reported by Zia et al. and Kruke et al.<sup>5,15</sup> Identified factors that affect outcome includes movement degree of a fracture, reduction perfection, fixation interne location, grade of pulverization of cortical bone posteriorly, and elapsed time from injury to the operative intervention.<sup>1,16</sup>

Orthopedic surgeons routinely encounter femur neck fracture which remain a challenging task in their clinical practices. Management of FNF fractures is still a debatable point over the years.<sup>12</sup> Broadly, if we study the treatment option or mode widely accepted is fixing internally the fracture through open or close methods in lesser age group and people without arthritic findings in the hip joint.<sup>9,14</sup> The primary and ultimate goal for fractured neck is to obtain the accurate reduction for re-establishing dubious circulation to the proximal femur, in the young population and avoiding post-operative convolutions such as non-union and avascular necrosis.<sup>5</sup>

Two or more usually 3 standard cannulated screws of 7.3mm cancellous type placed inside as "3 point principle" through which able to provide stable fixation under surgical expertise and that is how we did all

fixations of neck of femur fractures in the present study. It is stated and emphasized that FNF is a fracture of necessity and its intervention should be considered as early as possible in emergency so to retrieve dubious circulation to the femur head & avoid complexities like bony non-union and AVN.<sup>13,17</sup> These complications make hip liable to degenerative arthritic changes and between 20-36% revision hip surgery and hip replacement is reported.<sup>18</sup>

Non-union of bones after surgery is one of the complications that was observed in 2.94% patients during this study. There was a statistically significant relation ( $p < 0.05$ ) between non-union of bones with age group and duration of fracture in our present study. Araujo TP et al<sup>19</sup> Popelka O. et al<sup>7</sup> reported prevalence of bony non-union in agreement to current study while Zia et al<sup>5</sup> reported bony non-union in 12.4% cases. Avascular necrosis proceeds to sequential crumbling of the femur head which leads to future degenerative hip arthritis, making the need of revision or hip replacement essential. Past researches highlighted altered points with respect to the connection between age of patient to percentage of avascular necrosis. In this present study, the incidence of AVN after a non-displaced fracture was 6.47% (that is 13/201 patients). This finding is consistent with Pei et al. and Kang et al. that reported 8.3% and 5.4% of their patients developed post-operative AVN after non-displaced type I and II fractures.<sup>20, 21</sup> Whereas, Khoo et al reported the higher incidence of AVN (16.98%) in their patients.<sup>13</sup>

Current study hasn't found any significant relationship of AVN with age & gender of patient, type of fracture, mean hospital stay and duration between trauma and surgery. In contrast, C.D. Novoa-Parra et al has demonstrated a significant association between patient age and AVN.<sup>22</sup> On the other hand finding of current study are in agreement with that of Khoo et al. who reported no significant relation between frequency of AVN and age.<sup>13</sup> Moreover, C.D. Novoa-Parra et al, Kim et al. and Papakostidis et al. also demonstrated no significant relation between AVN and delay until surgery. These findings are also consistent with our study findings.<sup>(4, 17, 22)</sup>

**Limitations of study:** Short duration (3 years), shorter follow up with relatively younger age patients hav-

ing non displaced FNF were included. Any of these or more than one factor may have contributed to lesser prevalence of AVN during this study. All cases were managed by single technique of cannulated screws fixation without any comparative technique

#### Conclusion:

Based on the findings, the study concludes that fixation of neck of femur non-displaced fractures through cannulated hip screws remains an effective option with limited or minimal postoperative complications among younger patients.

#### Conflicts Of Interests:

Not any

#### Funding Source:

Nil

#### References:

- Ramadanov N, Toma I, Herkner H, Klein R, Behringer W, Matthes G. Factors that influence the complications and outcomes of femoral neck fractures treated by cannulated screw fixation. *Scientific reports*. 2020;10(1):1-758.
- Giordano V, Giordano M, Aquino R, Grossi JO, Senna H, Koch HA. How do orthopedic surgeons manage displaced femoral neck fracture in the middle-aged patient? Brazilian survey of 78 Orthopaedic surgeons. *Revistabrasileira de ortopedia*. 2019;54: (3):288-94.
- Khalid MU, Waqas M, Akhtar M, Nadeem RD, Javed MB, Gillani SFUHS. Radiological Outcome of Fracture of Neck-of-Femur Treated with Two versus Three Cannulated Screws Fixation in Adults. *Journal of the College of Physicians and Surgeons Pakistan*. 2019;29(11):1062-66.
- Kim JY, Kong GM, Park DH, Kim DY. Multiple cannulated screw fixation of young femoral neck fractures. *Pakistan journal of medical sciences*. 2015;31(6):1517-20.
- Zia OB, Siddiqui A, Iqbal F, Soomro SU, Bajwa AF. Cannulated screws fixation is usually the method of choice for NOF fracture specially in younger patients. *Journal of Pakistan Orthopaedic Association*. 2017;29(04):157-62.
- Papanna M, Tafazal S, Bell M, Giles S, Fernandes J. Femoral neck fractures in osteogenesis imperfecta treated with bisphosphonates. *Journal of children's orthopaedics*. 2017;11(3): 191-194.
- Araujo TP, Guimaraes TM, Andrade-Silva FB, Kojima KE, Silva Jdos S. Influence of time to surgery on the incidence of complications in femoral neck fracture treated with cannulated screws. *Injury*. 2014 Nov;45 Suppl 5:S36-9. doi: 10.1016/S0020-1383(14)7
- Koaban S, Alatassi R, Alharbi S, Alshehri M, Alghamdi K. The relationship between femoral neck fracture in adult and avascular necrosis and nonunion: a retrospective study. *Annals of medicine and surgery*. 2019;39:5-9.
- Ramallo DA, Kropf LL, Zaluski AD, Cavalcanti AdS, Duarte MEL, Guimarães JAM. Factors influencing the outcome of osteosynthesis in the fracture of the femoral neck in young adult patients. *Revistabrasileira de ortopedia*. 2019;54:408-415.
- Wang C-T, Chen J-W, Wu K, Chen C-S, Chen W-C, Pao J-L, et al. Suboptimal outcomes after closed reduction and internal fixation of displaced femoral neck fractures in middle-aged patients: is internal fixation adequate in this age group? *BMC musculoskeletal disorders*. 2018 Jun 9;19(1):190.
- Shu D-P, Xiao Y-P, Bei M-J, Ji T, Peng Y-J, Ma B, et al. Dynamic compression locking system versus multiple cannulated compression screw for the treatment of femoral neck fractures: a comparative study. *BMC musculoskeletal disorders*. 2020; 21: 230.
- Yin H, Pan Z, Jiang H. Is dynamic locking plate (Targon FN) a better choice for treating of intracapsular hip fracture? A meta-analysis. *International Journal of Surgery*. 2018;52:30-34.
- Khoo C, Haseeb A, Singh VA. Cannulated screw fixation for femoral neck fractures: A 5-year experience in a single institution. *Malaysian orthopaedic journal*. 2014;8(2):14-21.
- Lu Q, Tang G, Zhao X, Guo S, Cai B, Li Q. Hemiarthroplasty versus internal fixation in super-aged patients with undisplaced femoral neck fractures: a 5-year follow-up of randomized controlled trial. *Archives of orthopaedic and trauma surgery*. 2017;137(1):27-35.
- Do DNL, Kruke TM, Foss OA, Basso T. Reoperations and mortality in 383 patients operated with parallel screws for Garden I-II femoral neck fractures with up to ten years follow-up. *Injury*. 2016;47(12):2739-42.
- Blake C, Van Staden G, Van der Merwe J, Matshidza S. Management of femur neck fractures in young adults under the age of 60 years. *SA Orthopaedic Journal*. 2020;19(2):103-8.
- Papakostidis C, Panagiotopoulos A, Piccioli A, Giannoudis PV. Timing of internal fixation of femoral neck fractures. A systematic review and meta-analysis of the final outcome. *Injury*. 2015;46(3):459-66.
- Haider T, Schnabel J, Hochpöchler J, Wozasek GE. Femoral shortening does not impair functional outcome after internal fixation of femoral neck fractures in non-geriatric patients. *Archives of orthopaedic and trauma surgery*. 2018;138(11):1511-1517.

19. Popelka O, Skala-Rosenbaum J, Bartoška R, Waldauf P, Krbec M, Džupa V. Fracture type and injury-to-surgery interval as risk factors for avascular necrosis of the femoral head after internal fixation of intracapsular femoral neck fracture. *Acta chirurgiaeorthopaedicae et traumatologiaeCechoslovaca*. 2015;82(4):282-287.
20. Pei F, Zhao R, Li F, Chen X, Guo K, Zhu L. Osteonecrosis of femoral head in young patients with femoral neck fracture: a retrospective study of 250 patients followed for average of 7.5 years. *Journal of Orthopaedic Surgery and Research*. 2020;15(1):238.
21. Kang JS, Moon KH, Shin JS, Shin EH, Ahn CH, Choi GH. Clinical results of internal fixation of subcapital femoral neck fractures. *Clinics in orthopedic surgery*. 2016;8(2):146-152.
22. Novoa-Parra C, Perez-Ortiz S, Lopez-Trabucco R, Blas-Dobon J, Rodrigo-Perez J, Lizaur-Utrilla A. Factors associated with the development of avascular necrosis of the femoral head after non-displaced femoral neck fracture treated with internal fixation. *Revista Española de CirugíaOrtopédica y Traumatología (English Edition)*. 2019;63(3):233-8.