

FREQUENCY AND MORPHOLOGICAL TYPES OF GERM CELL TESTICULAR TUMOR IN VARIOUS AGE GROUPS.

Shanker Bhawani^{1*}, Mothiani B², Saddiqui R.B³

Abstract:

Objectives: To determine the frequency and morphological types of germ cell testicular tumor in various age groups among cases received at the Department of pathology, BMSI JPMC over a 5 year period.

Material and Method: A retrospective, descriptive study was conducted at the department of pathology BMSI JPMC and all testicular tumors received over a period of 5 year i.e.; from 1st January 2008 to 1st January 2013 were reviewed. All specimens were formalin fixed, routinely processed for paraffin embedding, sectioned and finally stained with Haematoxylin & Eosin using standard procedures. Special staining was performed where required.

Results: During the study period 2008 to 2013, all 21 cases of testicular tumor received were diagnosed as, germ cell tumor; consisting of Ten (47.6%) cases of single histopathological type and 11 (52.38%) cases of mixed germ cell tumors. Most of the cases presented in the 3rd and 4th decades. Amongst these seminoma was the most common (33.3%) tumor followed by Teratocarcinoma (Teratoma and Embryonal Carcinoma) (28.57%).

Conclusion: In this study the most frequently encountered malignancy is single histopathological type seminoma with the maximum number of cases seen in 3rd and 4th decade. Teratocarcinoma with combination was the commonest MGCT in 2nd to 4th decade, followed by a mixed embryonal carcinoma and seminoma seen in 3rd to 4th decade.

Key Words: Testicular tumor, MGCT, seminoma.

Introduction:

According to western published data testicular cancer is the commonest malignancy in young male between age 20-30 years in the United States¹ and the world wide incidence has almost doubled in the past few decades². A study conducted in Pakistan (1987) reported that testicular cancer comprises 3.8% of all malignancies³. According to the collective cancers registry report (1994-2009) by Shaukat Khanum cancer hospital, out of a total of 2113 cancers in males, 577 (36.6%) were of testicular origin⁴. Multiple studies conducted in different part of world showed that testicular germ cell tumors comprised 1-2% of all malignant neoplasm's in male⁵. Germ cell tumor comprise majority of adult testicular tumors (95-98%)^{6,7,8}. The WHO classification of testicular tumors broadly divides malignant germ cells tumor into: (1) Intratesticular (malignancy), (2) Malignant pure germ cell tumors (showing a single cell type), (3) Malignant mixed germ cell tumors (showing more than one histological pattern) and (4) Polyembryoma. The pure germ cell tumors include seminomas and nonseminomas (including embryonal carcinoma, teratoma, choriocarcinoma and yolk sac tumor). Germ cell tumor usually behaves aggressively, however mortality due to these lesion has decreased because of recent advances in management strategies⁹. Bilateral testicular involvement

by germ cell tumors is seen in 1.0% to 2.7%, but if both testis are undescended then risk of bilateral involvement rises to 15%.¹⁰ In this study we attempted to share our experience and compare the frequency of various morphological types of GCTT (Germ cell testicular tumor) in different age group with other studies.

Material And Methods:

A retrospective, descriptive study was conducted at the department of pathology BMSI JPMC and all testicular tumors received over a period of 5 year i.e. from 1st January 2008 to 1st January 2013 were reviewed. All specimens were formalin fixed, routinely processed for paraffin embedding, sectioned and finally stained with H&E using standard procedures. Special staining was performed where required.

Results:

During the 5 year study period a total of 21 cases of testicular tumor were received in our department and all were diagnosed as germ cell tumors including both single (pure) and mixed types. Age of the patients ranged from 11-50 years. 10 cases (47.62%) were diagnosed as pure germ cell tumors where's 11 cases (52.38%) were diagnosed as germ cell tumors with a mixed histological pattern. Among the germ cell tumors of single histological type (table:1) seminoma constituted the most encountered pathology with a total of 07 cases (33.3%), 02 cases of teratoma (mature) and 01 cases of embryonal carcinoma were also seen. Among germ cell tumors of mixed histology (table: 1) Teratocarcinoma constituted 28.57% of all cases with (06) cases, while seminoma and Embryonal carcinoma constituted (03 cases) and Yolk sac and embryonal carcinoma constituted 9.52% (2 cases) of all cases. Table:3 gives the age distribution for the different tumors in our study. The

1. Assistant professor of Pathology, Muhammad Medical college Mirpurkhas.
2. Consultant Physician Civil Hospital MPS
3. Assistant Professor of Pathology, Karachi Medical & Dental College.

age range for all tumors was 11-50 years with the mean age being 24.36%. Most of the patients (28.36%) were between 21-40 years of age. For seminoma the age range was 21-50 years mean age being 24.27 years. The age range for mixed germ cell tumor was 11-40 years mean (28.36%) with 6 out of 11 patients belonging to the 21-30 years age groups.

Table: 1 Various histopathological types of Germ cell tumor (n=21)

Morphological	Number of cases
Single histopathological type (10 cases)	
1.Seminoma	07 (33.3%)
2.Embryonal carcinoma	01 (4.76 %)
3.Mature Teratoma	02 (9.52%)
Mixed histopathological type (11cases)	
1. Teartocarcinoma (Teratoma + Embryonal carcinoma)	06 (28.57%)
2. Seminoma + Embryonal carcinoma	03 (14.28%)
3. Yolk Sac + Embryonal carcinoma	02 (9.52%)
Total	21

Table:-2 Histopathological diagnosis of testicular tumor with correlation to age groups. (n =21)

	Age Group wise Number of Cases (n=21)							
	0 - 10	11 - 20	21 - 30	31- 40	41- 50	51- 60	>70	
Seminoma			03	03	01			07
Embryonal Carinoma			01					01
Mature Teratoma			01	01				02
Embryonal Carinoma +Seminoma			01	02				03
Teatocarcinoma) (Embryonal Carinoma+ Mature Teratoma)		02	03	01				06
Embryonal Carinoma + Yolk sac Tumor			02					02
Total		02	11	07	01	00	00	21

Fig: 1 : Photomicrograph showing Schiller-Duval body in yolk sac tumor. (H&E 40 X) teratoma.(H&E 40 X)

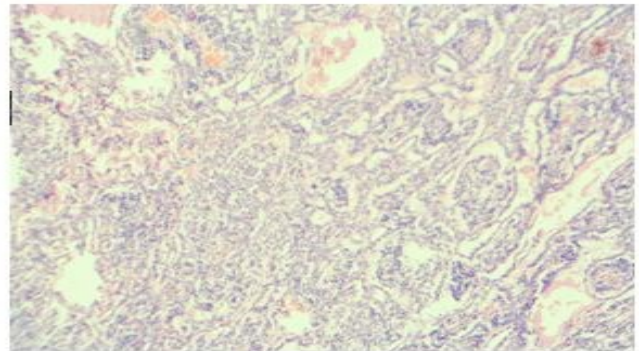


Fig: 2 : Photomicrograph showing seminoma. (H&E 40 X)

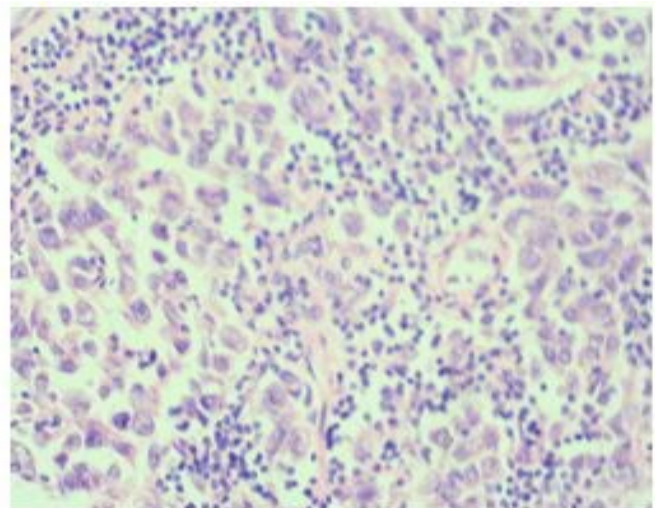
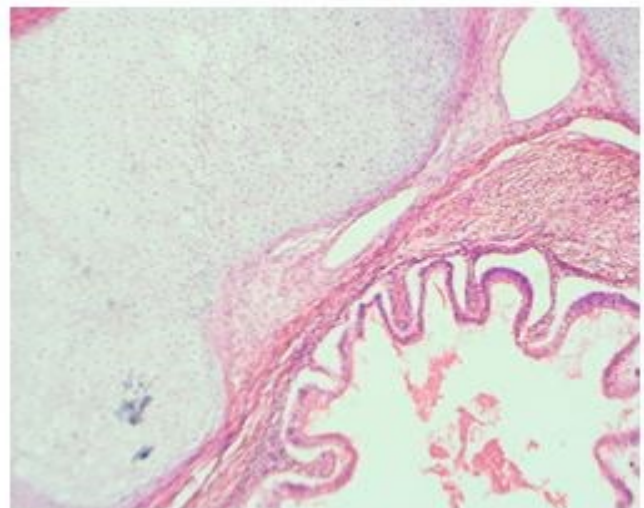


Fig: 3 : Photomicrograph showing element of mature teratoma. (H&E 40 X)



Discussion:

In this study the most commonly encountered pure germ cell tumors is seminoma, constituting 33.3% of all cases. Most of the patients belonged to the 3rd and 4th decade. These findings are in accordance with different studies conducted in the Indo-Pak subcontinent by Detora et al (1994) and Naqvi et al (2006) showing frequency of seminoma as 34% and 37% respectively with most of the cases belonging to the third and fourth decade of life. Our finding also correspond to the figures quoted in SKMCH annual registry report 2009, where seminoma was the most commonly encountered testicular tumor, constituting 31.16% of all testicular carcinomas and the most affected age group was 21-40 years⁴. However the published western data shows a comparatively higher incidence with seminoma constituting 56.4% of all cases of testicular tumors which could be due to slightly more sample size¹³. Mature teratoma in our study comprised 9.25% of all cases with most of the patients belonging to the 3rd and 4th decades of life. Our findings correspond closely with those of Gill et al¹⁴, where teratoma comprised 7% of all testicular tumor and most of the cases belonged to the 3rd and 4th decade of life. In our study embryonal carcinoma constituted 4.76% of all cases. The age group was 21-30 years. Similar findings were observed by Gill, where embryonal carcinoma comprised 2.35% of all cases. Amongst mixed germ cell tumor teratocarcinoma was the most commonly encountered tumor, constituting 28.57% of all testicular tumors in this study. Our finding corresponds closely with those of R. Avasthi et al (2008), where teratocarcinoma comprised 26%¹⁵. Low and high incidence of teratocarcinoma was observed and reported by Grahams and Kairs showing 40% and 6.8% respectively¹⁶. The age range for Teratocarcinoma in this study was 11-40 years.

These figures closely correspond to those quoted by Detora et al (1994), where most of the cases belonged to the 3rd and 4th decades of life¹². However, most of the cases in our series showing a combination of Teratocarcinoma belonged to a younger age between 11-30 years, as composed to the combination of embryonal carcinoma and seminoma which in this series was seen in 3rd & 4th decades. Embryonal carcinoma with seminoma observed in 14.28% of cases in this study. The age range in our study was 21-40 years. Our finding corresponds closely with Naqvi et al, where Embryonal carcinoma with seminoma constituted 18.8% of all testicular tumor¹¹. Embryonal carcinoma with yolk sac tumor was constituted 9.52% of cases in our study. In a study conducted by R Avasthi et al (2008), embryonal carcinoma and seminoma showed figure closely to study, constituting 11% of all cases of testicular tumors¹⁵.

Conclusion:

In this study the most frequently encountered malignancy is single histopathological type seminoma with the maximum number of cases seen in 3rd and 4th decade. Teratocarcinoma with combination was the commonest MGCT in 2nd to 4th decade, followed by a mixed embry-

nal carcinoma and seminoma seen in 3rd -4th decade.

References:

1. Devesa SS, Blot WJ, Stone BJ, Barry AM, Robert ET, Joseph F. Fraume Jr. Recent cancer trend in the United States. *J Nail Cancer Ins* 1995;87:175-82.
2. Bosl GJ, Bajorm D, Sheinfeld J, Motzer RJ: Cancer of the testis. In: Devita VI, HELMAN S, Rosenberg S eds. *Cancer principles and practices of oncology*. 5thed Philadelphia JB Lippincott.1997,pp1397-1014-25.
3. Jaffery N A, Zaidi SHM. Cancer in Pakistan. *JPMA* 1987;37:178-83.
4. Annual cancer registry report-2004. Shoukat Khanum Cancer Hospital and research center,p11.
5. Zubair A, Sahar AN, Nausheen Y, Akhater H, Aamir A, Naiser KM, Rasahida A, Naila K, Hassan P. Frequency of primary solid malignant neoplasms in both sexes, as seen in our practice. *J Ayub Med college* 2007;19:53-55.
6. Russal RCG; The gall bladder and bile ducts. Russel R.C.G Williams NS, Bulstrode CJK eds in Bailey and Loves Short Practice of Surgery 24thed 2004 pp 1095 -1113.Robbins and Cortan. Testis and epididymis.
7. Robbins pathological basis of disease 8thed.Philadelphia. W B sanders,2010,pp 1014-25.
8. D Schottenfeld. Testicular cancer In: D Schottenfeld Fraumeni JF Jr, eds. *Cancer Epidemiology and prevention*. New york:Oxford university press,1996:1207 -19.
9. Feuer EJ, Frey CM, Brawley OW, Nayfield SG, Cunningham JB, Geller NL, Bosl GJ and Kramer BS. After a treatment breakthrough: a comparison of trial and population- based data for advanced testicular cancer. *J ClinOncol*.1994;12:368-77.
10. Rosi and Ackerman Surgical pathology, 10thed.Elsevier, NewDelhli,India 2011pp1433-34.
11. Naqvi SQH, Ansari AL, Memon NA, Memon J M , Akhund AA. Correlation of Age with histopathological type of testicular tumors. *Gomal J Med Science* 2006;4: 24-27.
12. Detora A, Mathur DR, Vyas MC. A 18 years study of testicular tumors in Jodhpur, Western Rajasthan. *J Post grade Med* 1994; 40:68-70.
13. Biggs ML, Schwatz SM. Cancer of the testis. In: National cancer institute.
14. Gill MS, Shah SH, Soomro IN, Kayani N, Hassan SH. Morphological pattern of testicular tumors. *J Pak Med Association* 2000; 5 0:110-112.
15. A vasthi R, Chaudhary SC, Mohanty D, Mi- shra K. Testicular Mixed germ cell tumor metastasizing to heart. *JAPI* 2008;56:8-15.
16. Graham S, Gibson RW. Social epidemiology of Cancer of the testis. *Cancer* 1972; 29:1242.