A Rare Case of Disseminated Histoplasmosis in an Immunocompetent Young Male: Diagnostic Value of Bone Marrow Biopsy and Fungal Morphological Identification.

Muhammad Shayan Ashfaq[1*], Natasha Ali[2]

ABSTRACT:

The dimorphic fungus Histoplasma capsulatum causes histoplasmosis, an infection that can manifest as anything from a simple, self-limiting illness to a serious, widely spread illness. Fungal culture is still the gold standard for confirmation, but diagnosis is sometimes delayed by its slow development. Bone marrow analysis can offer a quick and accurate diagnostic substitute in these situations. We describe a male immunocompetent patient, age 21, who has had a persistent fever and malaise for three months that have not improved with empirical treatment. Repeated blood cultures and serologic testing came out negative, but laboratory studies showed cytopenia. Grocott-Gomori Methenamine Silver (GMS) and Periodic acid-Schiff (PAS) stain, on the other hand, revealed intracellular and extracellular yeast-like organisms in bone marrow aspirate and trephine biopsy that were morphologically consistent with Histoplasma capsulatum.

Keywords: Histoplasma capsulatum, disseminated histoplasmosis, bone marrow biopsy, cytopenia, fungal morphology.

Cite: Ashfaq SM, Ali N, A. Rare Case of Disseminated Histoplasmosis in an Immunocompetent Young Male: Diagnostic Value of Bone Marrow Biopsy and Fungal Morphological Identification. J Muhammad Med Coll. 17(1) April-Oct 2026

Introduction:

Histoplasma capsulatum is a systemic fungal disease caused by the dimorphic organism Histoplasma capsulatum. In healthy individuals, it frequently shows no symptoms or only mild signs. Nevertheless, in certain instances, it can result in a serious febrile illness. Among the endemic fungal infections, H. capsulatum is the leading cause of hospitalization, especially in regions where the fungus is commonly found.[1] The infection presents in three main types: acute primary, chronic, and disseminated. Histoplasma capsulatum is distributed globally, with a greater concentration in North and Central America, especially in areas linked to tainted bird or bat feces. The fungus is commonly found in caves, chicken coops, bat habitats, and places with bird nests, where spores are breathed in from the polluted soil or droppings.[2] Environmental factors such as soil composition and moisture play a key role in the proliferation of *Histoplasma* in these areas.[3] Histoplasmosis often presents with nebulous symptoms; clinical diagnosis can be challenging. Histopathological analysis, serological testing, and culture are the methods used for diagnosis; bone marrow biopsy is an essential procedure for prompt diagnosis in cases of dissemination.[4] Although cultural testing is thought to be the most accurate diagnostic technique, its lengthy incubation period may cause treatment to be delayed. Therefore, bone marrow samples must be evaluated histopathologically and cytologically for prompt identification, particularly in patients who present with fever and unexplained cytopenia.[5]

We describe a young, otherwise healthy man from Punjab, Pakistan, who developed widespread histoplasmosis. Exposure to agricultural soil may have been the cause of the infection. This report highlights the importance of bone morrow morphology for timely diagnosis of this potentially lethal infection.

Case report:

For three months, a 21-year-old male student majoring in agricultural engineering had been experiencing symptoms such as a low-grade fever, vomiting, left-sided upper abdominal pain, fatigue, and weight loss. His past medical history was unremarkable; no recurring infections or issues related to recent travel were known. Upon physical examination, he showed signs of hepatosplenomegaly and significant cervical lymphadenopathy. Laboratory tests revealed that the hemoglobin level was 7.8 g/dL, the platelet count was 13 x 10^9/L, the white blood cell (WBC) count was 4.63 x 10^9/L, and the corrected reticulocyte count was 2.9%. After being incubated for six weeks at both 25°C and 37°C, additional diagnostic tests—including a fungal culture—were performed, but the results were negative. Malarial antigens tested using an immunochromatographic kit were negative, and blood cultures showed no growth of organisms. The HIV test returned a non-reactive result. Serological analysis for *Brucella abortus* and *Brucella melitensis* antibodies displayed titers of <1:80. An abdominal ultrasound and other radiological evaluations revealed hepatosplenomegaly, but no apparent cause could be set up. A bone marrow examination was requested due to the patient fever of unknown cause. In addition to reactive lymphocytes, the blood film showed a leucoerythroblastic blood profile.

When the bone marrow aspirate smear was stained with Leishman, numerous round incentive cells with distinctive central clearing were seen (Figure-1). These provocations

1. Resident, Section of Hematology & Transfusion Medicine, Department of Pathology and Laboratory Medicine, Aga Khan University.
2. Associate Professor, Section of Hematology & Transfusion Medicine, Department of Pathology and Laboratory Medicine, Aga Khan University.

**=corresponding author :*

Email: shayanthebest911@gmail.com

Received: August 2026

Accepted: September 2026

were set up in clusters, both inside and outdoors histiocytes, with some displaying budding—a typical sign of Histoplasma capsulatum. To further validate the fungal infection, Grocott-Gomori Methenamine Silver (GMS) and Periodic acid-Schiff (PAS) stains were employed. (Figure-1) Both staining styles returned positive results, with the fungal factors appearing as dark, globular provocations. In addition, Hematoxylin and Eosin staining, Grocott-Gomori Methenamine Silver (GMS) and Periodic acid-Schiff (PAS) stains of the bone trephine sections showed clusters of *Histoplasma capsulatum*. (Figure-2)

The observed morphological characteristics – round provocations with central clearing, expiring forms, and their localization within macrophages (histiocytes) – explosively indicated a circulated infection caused by *Histoplasma capsulatum*. The treating doctor was instantly notified of these findings, and the case was started on intravenous broad-spectrum antifungal treatment.

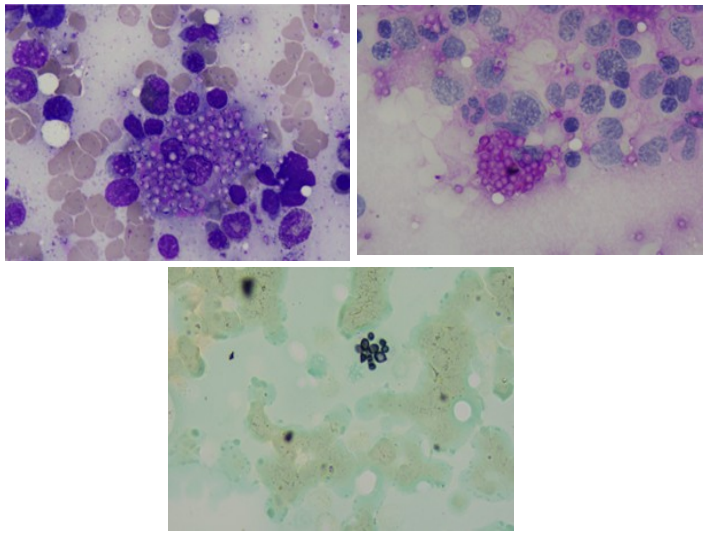

Figure No 1: Bone marrow aspirate showing yeast-like cells of histoplasmosis (Leishman stain, PAS stain and GMS stain; 100x).

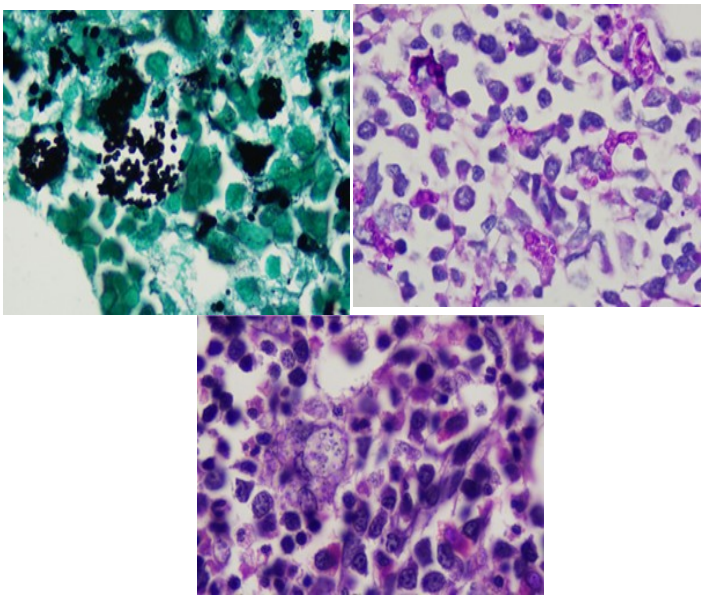

Figure No 2: Bone trephine section showing yeast-like cells of histoplasmosis (Leishman stain, PAS stain and GMS stain; 100x)

Discussion:

Histoplasmosis, which spreads through the air, usually affects individuals with weakened immune systems, such as those with HIV or specific blood cancers.[6] However, in recent times, people with healthy immune systems are also becoming infected, particularly in regions where they are often exposed to the fungus, leading to confusion and irritation.[5] The present case further supports this evidence, showing that even in healthy individuals who have prolonged exposure to the environment, a considerable fungal load and spread can happen. The vague symptoms such as fever, malaise, hepatosplenomegaly, and cytopenia can readily resemble those of other endemic conditions like visceral leishmaniasis or disseminated tuberculosis, which often leads to a delay in diagnosis.[7] Although culture is still the most common way to diagnose problems, its long incubation period makes it unsuitable for making quick clinical decisions.[8] A vital diagnostic alternative is provided by the histopathological and cytological identification of yeast forms in bone marrow or tissue samples.[5] In this particular case, the culture remained non-contributory, but the morphological identification of characteristic yeast-like organisms during the bone marrow examination facilitated an early diagnosis and prompt initiation of antifungal treatment. The organisms were identified by their small dimensions, narrow-based budding, and perinuclear halo, and were effectively visualized using GMS and PAS staining techniques. These characteristics are essential for differentiating Histoplasma from other intracellular organisms like Leishmania donovani, which does not exhibit budding and contains a kinetoplast.[5] Similar results have been seen in previous studies, when bone marrow morphology was primarily used to identify disseminated histoplasmosis in healthy persons, even in cases where cultures were delayed or negative.[5] As prior investigations have emphasized, the detection of yeast forms on bone marrow smears facilitates timely identification and the start of antifungal treatment.[9] A thorough cytomorphologic evaluation of bone marrow is an essential technique for the early detection of disseminated histoplasmosis, particularly in regions with limited access to sophisticated mycological testing, as demonstrated by the combined results of earlier research and the current case.[10]

The patient's background in agriculture and rural living indicates that exposure to contaminated soil is likely the main source of infection. Similar exposures have been noted in previously reported cases from South Asia, suggesting that there may be unrecognized endemic areas in this region.[11] It is crucial for clinicians and pathologists to enhance their awareness, as misdiagnosing conditions can result in delays or inappropriate treatments. In regions where tuberculosis is common, histoplasmosis might be overlooked because of similarities in clinical and radiological presentations.[7] Incorporating fungal stains routinely into bone marrow evaluations for patients presenting with unexplained fever and cytopenia can enhance diagnostic effectiveness and enable prompt management.[5] When treatment initiated early it significantly increases chances of survival, whereas a late diagnosis may lead to fatal results. While comprehensive follow-up data was lacking in this instance, swift identification and communication with the treating physician allowed for immediate therapeutic measures to be taken.[12]

In summary, this situation illustrates that individuals with a healthy immune system working in environments contaminated with fungi can develop disseminated histoplasmosis.

When culture and serology tests produce ambiguous findings, a bone marrow biopsy serves as a quick, readily available, and highly effective diagnostic method. Recognizing its cytomorphological characteristics can greatly minimize diagnostic hold-ups and enhance patient outcomes in areas where fungal infections are often overlooked.

Conflict of interest:

None

Patient's consent:

Telegraphic informed consent was obtained from the patient.

Competing interest:

The authors declared no conflict interest.

Disclaimer (Artificial intelligence):

Author(s) hereby declares that No generative AI technologies such as Large Language Models (ChatGPT, COPILOT, etc.) and text-to-image generators have been used during the writing or editing of this manuscript.

References:

1. Kauffman CA. Histoplasmosis: a clinical and laboratory update. Clin Microbiol Rev. 2007 Jan;20(1):115-32. doi: 10.1128/CMR.00027-06. PMID: 17223625; PMCID: PMC1797635.
2. Wheat LJ, Kauffman CA. Histoplasmosis. Infect Dis Clin North Am. 2003 Mar;17(1):1-19, vii. doi: 10.1016/s0891-5520(02)00039-9. PMID: 12751258.
3. de Perio MA, Benedict K, Williams SL, Niemeier-Walsh C, Green BJ et al. Occupational Histoplasmosis: Epidemiology and Prevention Measures. J Fungi (Basel). 2021 Jun 26;7(7):510. doi: 10.3390/jof7070510. PMID: 34206791; PMCID: PMC8306883.
4. Hage CA, Azar MM, Bahr N, Loyd J, Wheat LJ. Histoplasmosis: Up-to-Date Evidence-Based Approach to Diagnosis and Management. Semin Respir Crit Care Med. 2015 Oct;36(5):729-45. doi: 10.1055/s-0035-1562899. Epub 2015 Sep 23. PMID: 26398539.
5. Shaikh MS, Majeed Memon A. Disseminated histoplasmosis in an immuno-competent young male: Role of bone marrow examination in rapid diagnosis. Diagn Cytopathol. 2018 Mar;46(3):273-276. doi: 10.1002/dc.23834. Epub 2017 Oct 11. PMID: 29024456.
6. Adenis AA, Aznar C, Couppié P. Histoplasmosis in HIV -Infected Patients: A Review of New Developments and Remaining Gaps. Curr Trop Med Rep. 2014 Mar 28;1(2):119-128. doi: 10.1007/s40475-014-0017-8. PMID: 24860719; PMCID: PMC4030124.
7. Soeroso NN, Aida A, Pratiwi WB, Utama BSP, Syahruddin E, Sembiring RE. Chronic pulmonary histoplasmosis masquerading as tuberculoma: A case report and literature review. Int J Surg Case Rep. 2025 Aug;133:111555. doi: 10.1016/j.ijscr.2025.111555. Epub 2025 Jun 21. PMID: 40554937; PMCID: PMC12242457.
8. Azar MM, Hage CA. Laboratory Diagnostics for Histoplasmosis. J Clin Microbiol. 2017 Jun;55(6):1612-1620. doi: 10.1128/JCM.02430-16. Epub 2017 Mar 8. PMID: 28275076; PMCID: PMC5442517.
9. Agarwal P, Capoor MR, Singh M, Gupta A, Chhakchhuak A, Debatta P. An Unusual Presentation of Disseminated Histoplasmosis: Case Report and Review of Pediatric Immunocompetent Patients from India. Mycopathologia. 2015 Dec;180(5-6):359-64. doi: 10.1007/s11046-015-9917-y. Epub 2015 Jul 1. PMID: 26126955.
10. Bardia PC, Detroja KN, Maniar RC, Dharsandia HK. A case of disseminated histoplasmosis diagnosed by bone marrow aspiration in immunocompetent patient from nonendemic area, Rajkot, Gujarat. Indian J Pathol Microbiol. 2024 Jan-Mar;67(1):230-232. doi: 10.4103/ijpm.ijpm_200_22. PMID: 38358230.
11. Smith DJ, Soebono H, Parajuli N, Grijsen ML, Cavanaugh AM, Chiller T, Pudasaini P, Barros TC, Chakrabarti A. South-East Asia regional neglected tropical disease framework: improving control of mycetoma, chromoblastomycosis, and sporotrichosis. Lancet Reg Health Southeast Asia. 2025 Mar 27;35:100561. doi: 10.1016/j.lansea.2025.100561. PMID: 40225334; PMCID: PMC11987668.
12. Naji A, Baxter M, Kumi A, Camille Ozaeta J, Onuoha N et al. A fungal nightmare: A rare and deadly presentation of disseminated histoplasmosis. IDCases. 2024 Sep 20;38:e02084. doi: 10.1016/j.idcr.2024.e02084. PMID: 40206335; PMCID: PMC11980627.

Authors' contribution	
Muhammad Shayan Ashfaq	Conception, draft writing, References
Natasha Ali	Literature Search, Revision