Histological Alterations of Diazepam & Diclofenac Potassium in the Kidney of Epileptic Rat Model.

Muhammad Saqib Baloch[1], Muhammad Shahab Hanif [2,*], Hira Asif [3], Muhammad Raheem Bhurgri [4], Ayesha[5], Sanam [6].

ABSTRACT:

Objective: To evaluate the effects of diazepam (an anticonvulsant and anxiolytic agent) and diclofenac potassium (a non-steroidal anti-inflammatory drug) on the histopathological changes in renal tissues within an experimental rat model of epilepsy.

Methodology: A total of 32 male Wistar albino rats (2–4 months old, 200–250 g) were randomly assigned to four groups (n = 8 each): Epilepsy, Epilepsy + Diazepam, Epilepsy + Diclofenac potassium, and Epilepsy + Diazepam + Diclofenac potassium. Epilepsy was induced by intraperitoneal injection of penicillin under urethane anesthesia, and 30 minutes after seizure onset, diazepam (0.1 mg/kg), diclofenac potassium (10 mg/kg), or both were administered intraperitoneally. Kidney tissues were subsequently examined histopathologically for inflammatory infiltration, glomerular atrophy, tubular dilatation, flattening of the epithelial lining, epithelial shedding, vacuole formation, loss of brush borders, vascular congestion, and hemorrhage.

Results: No significant differences were observed in vacuolization, glomerular atrophy, tubular dilation, or hemorrhage between the diazepam and diclofenac potassium groups. However, both treatment groups demonstrated marked reductions in inflammation, vascular congestion, and thinning of the tubular epithelium compared to the Epilepsy + Diazepam group. Minimal brush border loss and tubular desquamation were noted in the epilepsy-only group, but these variables did not differ significantly among the three treatment groups.

Conclusion: The combined administration of diazepam and diclofenac potassium produced fewer adverse histopathological alterations in renal tissues compared to their individual use, suggesting that co-administration may mitigate renal toxicity and exert a comparatively protective effect.

Keywords: Epilepsy, diclofenac potassium, diazepam, kidney, Wistar albino rats.

Cite as: Baloch MS, Hanif MS, Asif H, Bhurgri MR, Ayesha, Sanam, Histological Alterations of Diazepam & Diclofenac Potassium in the Kidney of Epileptic Rat Model. J Muhammad Med Coll. 17(1) May-Oct 2026

Introduction:

It is a well-known fact that epilepsy is a very common neurological disorder and is experienced by nearly 1% of the global population.[1] It is one of the most common neurological disorders and is present at all stages of life, demanding a prolonged therapy.[1,2] Anti-epileptic drugs constitute the primary means of managing epilepsy and manage to control seizures of two-thirds of the epileptic population.[3] Drug effectiveness, adverse reactions, toxicity and price can influence the choice of anti-epileptic drugs. The role of kidneys in the excretion of drugs is very important and they often suffer from toxicity of drugs.[4]

1. Assistant Professor, Department of Anatomy, Muhammad Medical College, Mirpurkhas.
2. Associate Professor, Department of Anatomy, Muhammad Medical College, Mirpurkhas.
3. Lecturer, Department of Anatomy, Muhammad Medical College, Mirpurkhas.
4. Assistant Professor, Department of Anatomy, Muhammad Medical College, Mirpurkhas.
5. Associate Professor, Department of Anatomy, Akhtar Saeed Medical College, Lahore.
6. Senior Medical Officer, The Agha Khan Hospital and Medical College Foundation, Karachi.

*=corresponding author:
Email: shahab_hanifhhh@yahoo.com
Received: August 2026, Revised: October 2026
Accepted: October 2026

In spite of the uncertainty of the frequency of nephrotoxicity of anti-epileptic drugs, there were cases when anti-epileptic drugs induced kidney damage, and great care should be taken with their use.[5] Seizure control with minimal side effects is the top priority of epilepsy management. The drug diazepam, which belongs to the group of benzodiazepines, is used for treating severe epilepsy.[6] Diazepam undergoes intensive metabolism in the liver and is excreted from the body via urine, mostly as its metabolites.[7] The adverse effect of diazepam is its nephrotoxic activity along with hepatotoxicity. Inflammation contributes to the development of epilepsy. The enzyme cyclooxygenase-2 (COX-2) is a mediator of inflammation and an increased level of COX-2 is observed in epilepsy patients.[8] The action of non-steroidal anti-inflammatory drugs (NSAIDs) includes the inhibition of COX enzymes and reducing of the production of prostanoids.[9] Diclofenac potassium is a potent anti-inflammatory agent, analgesic and antipyretic medication.[10] In addition, NSAIDs have anti-inflammatory activity and they could be used for the treatment of epilepsy. The purpose of the current research was to evaluate the influence of diazepam and diclofenac potassium, and their mixture, on kidneys in case of penicillin-induced epilepsy in rats

Objectives:

To evaluate the effects of diazepam (an anticonvulsant and anxiolytic agent) and diclofenac potassium (a non-steroidal anti-inflammatory drug) on the histopathological changes in renal tissues within an experimental rat model of epilepsy.

Methodology:

Experimental Animals and Grouping:

This study was conducted at the Department of Anatomy,

Muhammad Medical College, Mirpurkhas, in accordance with national guidelines for animal research, with the experimental protocol carried out at Sindh Agriculture University, Tando Jam. Thirty-two male Wistar albino rats (2–4 months old, 200–250 g) were used, with sample size determined through standard power analysis based on previous studies. [11,12] The animals were housed under controlled environmental conditions with regulated temperature and humidity, a 12-hour light/dark cycle, and free access to food and water. Rats were randomly divided into four groups (n = 8 each): Epilepsy, Epilepsy + Diazepam, Epilepsy + Diclofenac potassium, and Epilepsy + Diazepam + Diclofenac potassium.

Induction of Seizures, Drug Administration, and Analysis:

Following a 24-hour fasting period, rats were anesthetized with urethane and epilepsy was induced by intraperitoneal injection of penicillin (500,000 IU). Seizure onset was confirmed by at least three characteristic signs, including immobility, eye closure, facial clonus, head nodding, forelimb clonus, rearing, or rearing with loss of balance.[13] Thirty minutes after induction, diazepam (5 mg/kg), diclofenac potassium (10 mg/kg), or both were administered intraperitoneally according to group allocation, while controls received saline. At the end of the experimental period, rats were sacrificed under anesthesia, and renal tissues were handled as detailed in previous studies.[14,15] Kidneys were dissected and fixed in 10% formaldehyde, processed by standard histological techniques, embedded in paraffin, sectioned, and stained with hematoxylin and eosin. Histopathological parameters were evaluated semi-quantitatively under light microscopy, and statistical analyses were performed using SPSS software with appropriate parametric and non-parametric tests, considering $p \leq 0.05$ as statistically significant.

Results:

In each research group, an experimental form of epilepsy was effectively generated. Tables 1 and 2 summarize the histological results found in the kidney tissues of each group, and Figure 1a-d displays representative microscopic pictures.

Inflammation:

It was found that there was a statistically significant difference between the four experimental groups (χ^2 = 16.936, p value = 0.001) in inflammatory cell infiltration. There was significant difference between the Epilepsy plus Diazepam group and Epilepsy group (Z = −3.254, p value = 0.001) and Epilepsy plus Diclofenac potassium group (Z = −2.821, p value= 0.005) in terms of inflammatory cell infiltration. The Epilepsy plus Diazepam plus Diclofenac potassium group did not show significantly less degree of inflammatory cell infiltration than the Epilepsy plus Diazepam group (Z = −1.118, p value = 0.266).

Vascular Congestion:

Vascular congestion showed significant variations across the groups (χ^2 = 17.241, p = 0.001). In comparison to the Epilepsy plus Diazepam group (Z = −3.303, p value = 0.001) and the Epilepsy plus Diclofenac potassium group (Z = −3.344, p value = 0.001), the Epilepsy group displayed noticeably less congestion. There was no statistically significant difference between the Epilepsy plus Diclofenac potassium group and the combination treatment group, however the Epilepsy plus Diazepam plus Diclofenac potassium group seemed to have reduced congestion (Z = −2.232, p value = 0.026).

Interstitial Hemorrhage:

Interstitial bleeding showed a significantly significant difference between the groups (χ^2 = 23.894, p less than 0.001). In comparison to the Epilepsy group, hemorrhagic regions were substantially more common in the Epilepsy plus Diazepam and Epilepsy plus Diclofenac potassium groups (p less than 0.001). The Epilepsy plus Diclofenac potassium and Epilepsy plus Diazepam groups, as well as the Epilepsy plus Diclofenac potassium and combination treatment groups, did not differ significantly. However, compared to the Epilepsy plus Diazepam group, there was a substantial decrease in bleeding in the Epilepsy plus Diazepam plus Diclofenac potassium group (Z = −3.292, p value = 0.001).

Cytoplasmic Vacuolization:

There was a significant difference in the degree of cytoplasmic vacuolization between the groups (F = 12.775, p value < 0.001). The group with epilepsy had the least amount of vacuolization. When compared to the Epilepsy plus Diclofenac potassium and combined therapy groups, the Epilepsy plus Diazepam group showed more extensive vacuolization, although there was no statistically significant difference.

Glomerular Shrinkage:

Regarding glomerular shrinkage, there was a significant difference between the groups (χ^2 = 19.576, p value < 0.001). Glomerular shrinkage was substantially higher in the Epilepsy plus Diazepam group than in the Epilepsy group (Z = −3.705, p value = 0.001). The Epilepsy plus Diazepam and Epilepsy plus Diclofenac potassium groups did not vary statistically significantly. The Epilepsy plus Diclofenac potassium group experienced higher glomerular shrinkage than the combined treatment group, although this difference was not statistically significant.

Tubular Dilatation:

Tubular dilatation showed significant intergroup variations (χ^2 = 19.118, p value < 0.001). When compared to the Epilepsy group, tubular dilatation was considerably higher in the Epilepsy plus Diazepam group (Z = −3.336, p value = 0.001). Although the Epilepsy plus Diazepam group showed higher dilatation than the Epilepsy plus Diclofenac potassium group, this difference was not statistically significant. The Epilepsy plus Diazepam plus Diclofenac potassium group showed a significant decrease in tubular dilatation when compared to the Epilepsy plus Diazepam group (Z = −3.243, p value = 0.001).

Loss of Brush Border:

Regarding tubular brush boundary loss, there was a significant difference between the groups (χ^2 = 16.696, p value = 0.001). Brush border loss was substantially higher in the Epilepsy plus Diazepam group than in the Epilepsy group (Z = −3.292, p value = 0.001). Comparing the Epilepsy plus Diazepam group to the Epilepsy plus Diclofenac potassium group or the combined treatment group, however, did not reveal any significant changes.

Tubular Epithelial Thinning:

There were significant differences in tubular epithelial thinning between the groups (χ^2 = 18.351, p value less than 0.001). The Epilepsy plus Diazepam group showed the most significant epithelial thinning (Z = −3.393, p value = 0.001). When compared to the Epilepsy plus Diazepam group, there was a decrease in epithelial thinning in the combination treatment group, although this difference was not statistically significant.

Epithelial Desquamation:

Regarding epithelial desquamation, there were significant differences between the groups (χ^2 = 18.870, p value less

than 0.001). In comparison to the Epilepsy group, the Epilepsy plus Diazepam and Epilepsy plus Diclofenac potassium groups showed noticeably higher amounts of desquamation. The Epilepsy plus Diazepam and Epilepsy plus Diclofenac potassium groups did not vary statistically significantly. The combined treatment group had less severe epithelial desquamation, although this decrease was not statistically significant.

Serum Biochemical Parameters:

Significant differences were found in all serum biochemical parameters between the groups. The highest creatinine and urea concentrations were recorded in the Epilepsy plus Diazepam group, while the lowest values were seen in the combination of Epilepsy plus Diazepam plus Diclofenac group. Lowest sodium concentration was recorded in the Epilepsy plus Diazepam group, while highest potassium concentration was recorded in the Epilepsy plus Diazepam group. All the differences were significant ($p \leq 0.002$).

Oxidative Stress Markers:

Significant differences were found in all oxidative stress parameters ($p < 0.001$). The highest MDA levels were observed in the Epilepsy plus Diazepam group, while the lowest SOD and catalase levels were recorded in this group. The combination of Epilepsy plus Diazepam plus Diclofenac group showed lower MDA levels and higher SOD and catalase levels than individual groups of drugs.

Table 1. Normally Distributed Histopathological Parameters (Mean ± SD).

Histopathological Parameters	Ep (n = 8)	Ep + Dzp (n = 8)	Ep + Dicp (n = 8)	Ep + Dzp + Dicp (n = 8)	p-value
Vacuolization	0.00 ± 0.00^a	3.00 ± 0.86^b	1.50 ± 0.52^b	2.00 ± 1.17^b	0.003
Tubular Necrosis	0.25 ± 0.46^a	2.75 ± 0.71^c	2.25 ± 0.89^b	1.50 ± 0.93^b	<0.001
Interstitial Edema	0.38 ± 0.52^a	2.50 ± 0.53^c	2.13 ± 0.64^b	1.38 ± 0.74^b	<0.001
Cellular Degeneration	0.50 ± 0.53^a	2.88 ± 0.64^c	2.25 ± 0.71^b	1.63 ± 0.74^b	<0.001

^{a}, ^{b}, ^{c} = Means with different superscripts differ significantly at $p < 0.05$

Table 2. Non-Normally Distributed Histopathological Parameters (Median, IQR).

Histopathological Parameters	Ep (n = 8)	Ep + Dzp (n = 8)	Ep + Dicp (n = 8)	Ep + Dzp + Dicp (n = 8)	p-value
Inflammation	0.5 (1)?	4 (1)?	2(1)?	2 (1)?	0.001
Congestion	1 (0)??	3 (1)?	1 (1)?	2 (1)?	0.001
Hemorrhage	0 (0)?	2 (1)?	1 (2)?	1 (2)?	0.001
Glomerular Shrinkage	0 (1)?	3 (1)?	2 (2)?	2 (2)?	0.001
Tubular Dilation	0 (1)?	3 (1)?	1 (2)?	3 (1)?	0.001
Loss of Brush Border	0 (1)?	3 (2)?	3 (1)?	1 (2)?	0.001
Tubular Epithelium Thinning	0 (1)?	1 (1)?	1 (1)?	2 (1)?	0.001
Desquamated Epithelium	0 (0)?	3 (1)?	1 (1)?	2 (2)?	<0.001

Different superscripts indicate significance using Kruskal-Wallis + Dunn's test

Table 3. Serum Biochemical Parameters (Mean ± SD).

Histopathological Parameters	Ep	Ep + Dzp	Ep + Dicp	Ep + Dzp + Dicp	p-value
Creatinine (mg / dL)	0.62 ±0.08^a	1.85 ±0.22^c	1.42 ±0.19^b	1.05 ±0.17^b	<0.001
Urea (mg / dL)	28.5 ±3.2^a	68.2 ±6.4^c	55.6 ±5.7^b	42.1 ±4.8^b	<0.001
Sodium (mEq / L)	142 ±3.1^a	135 ±4.1^b	137 ±3.2^b	139 ±2.1^{ab}	0.002
Potassium (mEq / L)	4.1 ±0.3^a	5.8 ±0.6^c	5.2 ±0.5^b	4.6 ±0.4^b	<0.001

Serum creatinine, urea, and potassium levels were significantly elevated, while sodium levels were reduced in the Ep plus Dzp group compared with Ep. These alterations were partially ameliorated by Dicp treatment, particularly in the combined-treatment group ($p = 0.002$).

Table 4. Oxidative Stress Markers.

Parameters	Ep	Ep + Dzp	Ep + Dicp	Ep + Dzp + Dicp	p-value
MDA (nmol / mg)	1.2 ± 0.2^a	4.8 ± 0.7^c	3.9 ± 0.6^b	2.7 ± 0.5^b	<0.001
SOD (U / mg)	9.5 ± 1.2^a	3.2 ± 0.8^c	4.6 ± 0.9^b	6.8 ± 1.0^b	<0.001
Catalase (U / mg)	52 ± 6.0^a	21 ± 5.2^c	30 ± 4.3^b	40 ± 4.1^b	<0.001

The Ep plus Dzp group showed significantly increased MDA (Malondialdehyde) levels and reduced SOD (Superoxide dismutase) and catalase activities compared with Ep. Dicp treatment significantly attenuated these oxidative stress changes, with greater improvement observed following combined treatment ($p<0.001$).

Figure 1: Histopathological alterations in the renal cortex among different experimental groups (H&E x 400). (A) Normal renal corpuscles, renal tubules, and convoluted tubules. (B) Renal tubule necrosis and degeneration. (C) Comparatively reduced tubular degeneration and renal congestion, (D) Markedly reduced renal congestion and near normal architecture.

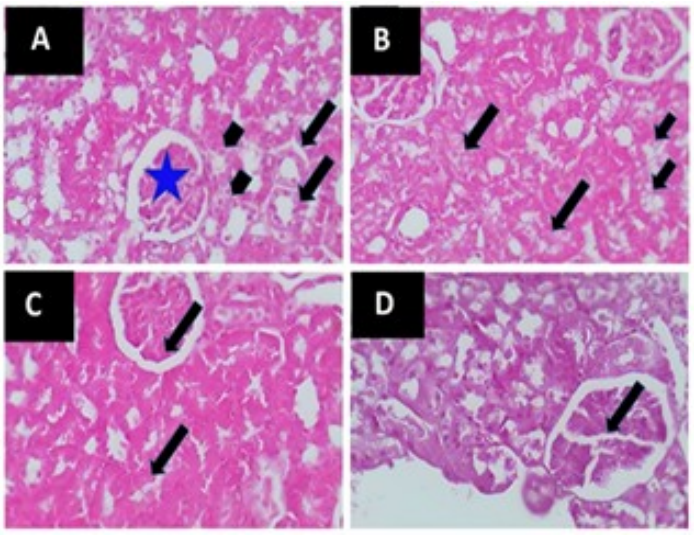

Discussions:

Epilepsy is a common neurological disorder that occurs in all age categories.[16,17] The disease affects more than 50 million individuals worldwide and involves repeated spontaneous attacks.[2] Treatment of epilepsy is provided through antiepileptic drugs, but their toxicity still remains a problem and causes damage to many organs including the kidney.[18] As we know, the kidney takes part in homeostatic processes including electrolyte balance and waste product removal from the body. It was found out that antiepileptic drugs such as valproate and carbamazepine lead to impairment of renal function.[19,20] In line with previous research results, this study revealed that antiepileptic drugs lead to changes in kidneys structure and functions. However, despite its popularity, diazepam, which belongs to the class of benzodiazepines, has been shown to cause kidney damage.[21] This is because the nephrotoxicity of diazepam can be explained by the decreased blood flow to the kidneys and direct cellular toxicity.[21] The results of the research conducted by Afolayan et al.[21] showed higher values of urea and creatinine accompanied by damage in the structure of the kidney upon diazepam treatment. This is consistent with the current research where increased levels of creatinine, urea and potassium were observed. High values of MDA and decreased activity of antioxidant enzymes (SOD and catalase) in the group treated with diazepam point out the increased level of lipid peroxidation and the weakened antioxidant system in the group under the influence of the drug.

The use of Diclofenac potassium, a non-steroidal anti-inflammatory drug (NSAID), showed relatively less kidney effects. Since NSAIDs cause impairment of kidney function by inhibition of prostaglandin formation and changes in kidney hemodynamics, diclofenac also has anti-inflammatory activity, which could be helpful in epilepsy patients.[22,23] There are earlier research findings showing the effectiveness of diclofenac in decreasing the severity of seizures and inflammatory mediators like TNF-α and IL-6.[23] In this current study, diclofenac administration led to decreased levels of biochemical and oxidative stress markers than in the case of diazepam only. This indicates a protective or modulatory action on account of inflammation and oxidative stress. Moreover, diclofenac activates KCNQ potassium channels that stabilize neuronal excitability.[24] Diazepam combined with diclofenac potassium proved to give the best results. The biochemical parameters, oxidative stress, and histopathology showed significant improvement from those seen with diazepam treatment alone. This confirms earlier studies which found that drug combinations could help reduce toxicity without compromising their therapeutic effectiveness. Careful analysis of the episodes of seizures also confirmed the final results. Diazepam caused a significant reduction in seizures intensity and increased latency and hence it proves its anticonvulsant activity. Diclofenac showed some anticonvulsant activity, while the drug combination had no adverse effect on efficacy. This experiment shows that although diazepam is effective in controlling convulsions, it causes severe damage to the kidney and oxidation. Diclofenac potassium when used together with diazepam, helps to minimize these side effects and improve the overall results. Nevertheless, because of the known side effects of NSAIDs, dose control is necessary. The limitations of this study are related to the absence of molecular and prolonged analysis. Further studies involving biochemical and molecular analysis are recommended.

Conclusion:

The combined administration of diazepam and diclofenac potassium produced fewer adverse histopathological alterations in renal tissues compared to their individual use, suggesting that co-administration may mitigate renal toxicity and exert a comparatively protective effect.

References:

1. Chen Z, Brodie MJ, Ding D, Kwan P. Editorial: Epidemiology of epilepsy and seizures. Front Epidemiol. 2023 Aug 30;3:1273163. doi: 10.3389/fepid.2023.1273163. PMID: 38455942; PMCID: PMC10911047.
2. Eslamian M, Shafiei H, Mojahed F, Bahreini, A. Prevalence of Epilepsy in Children and Adolescents Worldwide: A Literature Overview. Health Providers.2024; 4 (2), 99-108. doi:10.22034/hp.2024.485254.1047
3. Kim Y, Jang Y. A narrative review of antiseizure medication adherence in epilepsy: determinants to clinical implications. Encephalitis. 2026 Jan;6(1):1-7. doi: 10.47936/encephalitis.2025.00129. Epub 2026 Jan 10. PMID: 41530931; PMCID: PMC12800450.
4. Tomson T, Zelano J, Dang YL, Perucca P. The pharmacological treatment of epilepsy in adults. Epileptic Disord. 2023 Oct;25(5):649-669. doi: 10.1002/epd2.20093. Epub 2023 Jul 8. PMID: 37386690.
5. Angus-Leppan H, Sperling MR, Villanueva V. Antiseizure medications (antiepileptic drugs) in adults: starting, monitoring and stopping. J Neurol. 2023 Jan;270 (1):573-581. doi: 10.1007/s00415-022-11378-3. Epub 2022 Sep 24. PMID: 36153467.
6. Kienitz R, Kay L, Beuchat I, Gelhard S, von Brauchitsch S, at al. Benzodiazepines in the Management of Seizures and Status Epilepticus: A Review of Routes of Delivery, Pharmacokinetics, Efficacy, and Tolerability. CNS Drugs. 2022 Sep;36(9):951-975. doi: 10.1007/s40263-022-00940-2. Epub 2022 Aug 16. PMID: 35971024; PMCID: PMC9477921.
7. Alsfouk BA, Al-Kuraishy HM, Al-Gareeb AI, Abdelaziz AM, Ismail A, et al. The potential role of COX-2/PGs signaling pathway in epileptogenesis and associated neuroinflammation: collusions or serendipity. Neurol Sci. 2026 Feb 2;47(2):218. doi: 10.1007/s10072-025-08679-6. PMID: 41622366.
8. Satar, Hind A.; Yousif, Emad; and Ahmed, Ahmed. "DICLOFENAC: A Review on Its Synthesis, Mechanism of Action, Pharmacokinetics, Prospect and Environmental Impact," Al-Mustaqbal Journal of Pharmaceutical and Medical Sciences:2024; 2 (3). doi:10.62846/3006-5909.1017
9. Kapo SM, Rakanović-Todić M, Burnazović-Ristić L, Kusturica J, Ćesić AK, Ademović E, et al. Analgesic and anti-inflammatory effects of diclofenac and ketoprofen patches in two different rat models of acute inflammation. Journal of King Saud University-Science. 2023;35(1):102394. doi:10.1016/j.jksus.2022.102394.
10. Meghji K. A, Talpur R. A, Uqaili A. A, Nizammani, Y. M, Kazi, N, Nizammani, G. S.Resveratrol attenuates oxidative stress in chemotherapy induced acute kidney injury: an experimental rat model. Khyber Medical University Journal.2029; 11(2), 85-9. doi:10.35845/kmuj.2019.19114
11. Hanif M. S, Baloch, M. S, Meghji K. A, Abbas, A, Kashif S,Qureshi R. Histopathological changes in the gastric

mucosa induced by carbaryl toxicity: an experimental rat model. Khyber Medical University Journal,2020; 12 (2), 137-42. doi:10.35845/kmuj.2020.19896 .
12. Chitra Phalak, Smeeta Sadar. Animal models used in the screening of antiepileptic drugs. International Journal of Pharmaceutical Sciences and Research. IJPSR. 2022; 13 (2). doi: 10.13040/IJPSR.0975-8232.13(2).612-20.
13. Memon TF, Meghji KA, Kashif S, Nadeem F, Memon AA, Thalo AA. Protective effects of melissa officinalis extract against lead-induced toxicity in hepatic, renal and testicular tissues of male rats. Gomal Journal of Medical Sciences. 2025;23(4):412-7. doi:10.46903/gjms/23.4.2040
14. Meghji KA, Memon TF, Ahmed I, Memon SG, Noor N, Abbas A. Nephroprotective effects of L-Arginine against chemotherapy induced acute kidney injury in wistar rats. Journal of Islamabad Medical & Dental College. 2020;9(4):249-55. doi:10.35787/jimdc.v9i4.535.
15. Pellinen J, Foster EC, Wilmshurst JM, Zuberi SM, French J. Improving epilepsy diagnosis across the lifespan: approaches and innovations. Lancet Neurol. 2024 May;23(5):511-521. doi: 10.1016/S1474-4422(24)00079-6. PMID: 38631767. .
16. Waris A, Siraj M, Khan A, Lin J, Asim M, Alhumaydh FA. A Comprehensive Overview of the Current Status and Advancements in Various Treatment Strategies against Epilepsy. ACS Pharmacol Transl Sci. 2024 Nov 1;7(12):3729-3757. doi: 10.1021/acsptsci.4c00494. PMID: 39698272; PMCID: PMC11650742. .
17. Ahmad Mir M, Bashir Malik A, Qadrie Z, Altaf Dar M. Adverse Reactions Caused by Antiepileptic Medications in Real-World Medical Settings. International Journal of Current Research in Physiology and Pharmacology.2023; 7(Suppl 3), 25-35. Available from https://ijcrpp.com/index.php/ijcrpp/article/view/87. .
18. Anguissola G, Leu D, Simonetti GD, Simonetti BG, Lava SAG, Milani GP, Bianchetti MG, Scoglio M. Kidney tubular injury induced by valproic acid: systematic literature review. Pediatr Nephrol. 2023 Jun;38(6):1725-1731. doi: 10.1007/s00467-022-05869-8. Epub 2023 Jan 16. PMID: 36645492; PMCID: PMC10154265.
19. Esteghamati M, Moayedi A, Hoseinzadeh E, Zoghi G. Comparison of the Effects of Sodium Valproate and Carbamazepine on Renal Function in Children With Epilepsy. Hormozgan Medical Journal. 2022; 26(3), 145-149. SID. https://sid.ir/paper/1006692/en Esteghamati M, Moayedi A, Hoseinzadeh E, Zoghi G. Comparison of the Effects of Sodium Valproate and Carbamazepine on Renal Function in Children With Epilepsy. doi: 10.34172/hmj.2022.25.
20. Afolayan K A, Owoade AO. “The Haematotoxicity and Nephrotoxicity Effects of Diazepam Administration in Male Albino Rats”. Asian Journal of Research in Biochemistry.2024; 14 (6):58-70. doi:10.9734/ajrb/2024/v14i6327.
21. Klomjit N, Ungprasert P. Acute kidney injury associated with non-steroidal anti-inflammatory drugs. Eur J Intern Med. 2022 Jul;101:21-28. doi: 10.1016/j.ejim.2022.05.003. Epub 2022 May 6. PMID: 35534373.
22. Erdogan A, Erdogan MA, Gurgul S, Erbas O. Effects of Diclofenac Sodium on Seizure Activity in Rats with Pentylenetetrazole-Induced Convulsions. Neurochem Res. 2023 May;48(5):1412-1423. doi: 10.1007/s11064-022-03838-z. Epub 2022 Dec 6. PMID: 36474102.
23. Laghetti P, Altamura C, Dell'Atti S, Desaphy JF, Saltarella I. Nonsteroidal Anti-Inflammatory Drugs as Modulators of Cation Channels: Fenamates Repurposing in Channelopathies. ChemMedChem. 2025 Oct 15;20 (20):e202500301. doi: 10.1002/cmdc.202500301. Epub 2025 Sep 14. PMID: 40600901; PMCID: PMC12530847.

Authors' Contribution	
Muhammad Saqib Baloch	Conception and design, Drafting of the article, Critical revision of the article for important, Final approval and guarantor of the article
Muhammad Shahab Hanif	Collection and assembly of data Critical revision of the article for important intellectual content
Hira Asif	Drafting of the article, Critical revision of the article for important intellectual content
4Muhammad Raheem	Statistical expertise Analysis and interpretation of the data
Ayesha	Collection and assembly of data
Sanam	Collection and assembly of data